

An updated review of immunotherapy in esophageal cancer: PD-L1 footprint

JUAN YAO^{1*}, XIAOYAN TAN^{2*}, YANPING SHA^{1*}, YURAO CHEN¹, RONGHUAI CHEN¹,
DONGPING SHI³

¹Department of Radiation Oncology, Huaian Hospital of Huaian City (Huai'a Cancer Hospital), Huaian, Jiangsu 223200, P.R. of China

²Department of Obstetrics and Gynecology, Huaian Hospital of Huaian City (Huai'an Cancer Hospital), Huaian, Jiangsu 223200, P.R. of China

³Department of Infection, Huaian Hospital of Huaian City (Huai'a Cancer Hospital), Huaian, Jiangsu 223200, P.R. of China

*These authors contributed equally to this work.

Abstract

Esophageal cancer is considered one of the most significant challenges to public health worldwide. While various therapeutic options exist for esophageal cancer, including chemotherapy, radiotherapy, and surgery, several adverse effects of these medications have been reported. Therefore, a new generation of therapeutic lines should be applied to minimize complications. In this regard, immunotherapy is a novel approach that aims to kill tumor cells directly by targeting them. Specifically, monoclonal antibodies can target specific markers of esophageal cancer tumor cells, keeping other normal cells safe. Multiple monoclonal antibodies optimized for esophageal cancer, such as pembrolizumab, ramucirumab, trastuzumab, nivolumab, and ipilimumab, are available. On the other hand, esophageal cancer tumor cells express a specific inhibitory ligand and its receptor called programmed cell death, which can suppress T cell immune responses. This receptor provides an inhibitory signal, causing the highest expression of the PD-L1 ligand on tumor cells. The outcomes of this interaction lead to the suppression of the activation and function of T lymphocytes. Therefore, immunotherapy for esophageal cancer targeting the PD-1/PD-L1 pathway has shown a remarkable correlation with cancer care. This study presents a comprehensive review of the latest findings related to immunotherapy in esophageal cancer.

Key words: esophageal cancer, monoclonal antibody, immunotherapy, PD-1/PD-L1, chemotherapy.

(Cent Eur J Immunol 2024; 49 (1): 77-90)

Introduction

Esophageal cancer (EC) is an important public health problem [1] which was identified as the sixth leading cause of cancer death worldwide [2]. Due to the quick spread and high mortality rate, EC cancer is also considered as one of the most serious tumor diseases in the world [3]. Furthermore, EC is the eighth most common malignant cancer (3.2% of all cancer cases). The highest rates of this disease have been recorded in East Asia, East and South Africa, while the lowest rates have been observed in West Africa [4]. Studies have shown that EC has been diagnosed more in men than in women in the last 40 years, and the incidence and strong predominance of this disease among men have slightly increased [5]. Histologically, there are two main types: adenocarcinoma of the esophagus (ACE), which is prevalent in western populations, and squamous cell carcinoma (SCC), which is most common in Asian populations [6, 7]. In line with the risk factors for EC, according to studies, there are risk factors for esophageal

squamous cell carcinoma (ESCC), which are alcohol and tobacco consumption, hot drinks, poor oral hygiene, genetic mutation in enzymes that metabolize alcohol, burning injuries, exposure to chest radiation, nutritional deficiencies, low socioeconomic status, as well as two disorders called tylosis and achalasia [8, 9]. Also, there is direct contact between carcinogens in tobacco and the esophageal mucosa, which further contributes to the risk of esophageal squamous cell carcinoma. There are various therapeutic options for EC, including chemotherapy (CT) [10-13], radiotherapy (RT) [10], surgery [10] and, for better diagnosis or more advanced types, endoscopic procedures [11-14]. Notably, these mentioned therapeutic methods are associated with some serious disadvantages and many side effects for the patients. For instance, chemotherapy impacts regular cells and the immune system, potentially causing cancer recurrence. Hence, it is crucial to explore new therapeutic drugs without such complications [10].

Immunotherapy stands out as an innovative option, with numerous reported advancements. The mode of ac-

Correspondence: Dongping Shi, Department of Infection, Huaian Hospital of Huaian City (Huai'a Cancer Hospital), No. 19, Shanyang Road, Huaian, Jiangsu 223200, P.R. of China, e-mail: 1291083736@qq.com
Submitted: 11.05.2023, Accepted: 15.12.2023

tion of monoclonal antibodies (mAbs) is promoting the immune system, targeting specific markers of EC tumor cells. Furthermore, these mAbs such as pembrolizumab, ramucirumab, trastuzumab nivolumab, etc., in different treatment lines could be applied.

The first line of treatment is the CT method, which can delay tumor growth and reduce the burden of tumor mass and improve the 5-year survival of cancer patients [15-17]. In line with the treatment of EC, it has been shown in research that in addition to the surgical approach to this tumor, whenever CT, RT and immunotherapy are used, they can have advantages for the treatment of this cancer [18]. Studies have shown that patients with EC who undergo CT have reduced skeletal muscle mass or sarcopenia as complications of infection [19-22]. Another side effect of CT and chemoradiotherapy (CRT) is loss of appetite, deterioration of nutritional status, diarrhea and neutropenia [23-26]. In addition, treatment with CT and methods based on it can damage DNA and activate the complex cell signaling network, which itself causes the cell cycle to stop and initiates apoptosis [15]. As mentioned above, in order to enhance the quality of life and increase the survival of patients with EC, immunotherapy is a suitable candidate for patients with EC [27, 28]. However, the cancer cells of this lethal tumor after CT and the initial response to that treatment often develop multidrug resistance, which leads to recurrence of the tumor [16, 17].

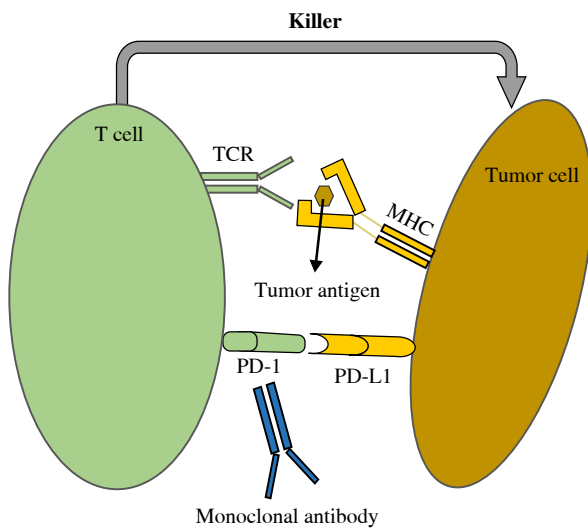


Fig. 1. Mode of action of monoclonal antibody. Anti-PD-1/PD-L1 antibody suppresses interaction between PD-1 and PD-L1. Generally, tumoricidal function of T cells can be hindered by PD-1 and PD-L1. However, monoclonal antibodies overcome this inhibitory effect. Consequently, T cells kill the tumor cells by receiving tumor antigens from MHC *via* TCR. PD-1 – programmed cell death-1, PD-L1 – programmed cell death ligand-1, TCR – T cell receptor, MHC – major histocompatibility complex

According to researchers, the main goal of immunotherapy to treat cancer is to overcome inhibition of the immune system by the tumor. Unlike CT, immunotherapy and targeted therapies are designed to attach specific molecules that are maximally expressed by the tumor such as HER-2, CEA, CA19-9 and CA15-3 [29]. Several studies show that immunotherapy has made a large change in the treatment of EC, and its outcomes include better quality of life, tolerable toxicity, high effectiveness, and improved survival rate [11, 13]. Furthermore, immunotherapy is effective in the treatment of other solid tumors and has led to the recovery of many cancer patients [30]. Programmed cell death (PD) and its ligand are expressed highly on the surface of tumor cells and they can suppress T cell immune responses. Some studies on programmed cell death-1 (PD-1)/programmed death-ligand 1 (PD-L1) ligands indicated the presence of PD-1 as a protein on the surface of T lymphocyte cells. This receptor provides an inhibitory signal which results in the highest expression of PDL-1 ligand on tumor cells. The outcomes of this interaction lead to inhibition of the activation and performance of T lymphocytes [31]. Therefore, immunotherapy of EC with the effect on PD-1/PD-L1 has illustrated a remarkable correlation with cancer care [32]. In this study, a comprehensive review of the latest findings related to immunotherapy in EC was performed.

Pembrolizumab mAb in esophageal cancer

There are complementarity-determining regions (CDRs) derived from mouse anti-human PD-1 monoclonal antibodies, and framework and constant regions derived from human IgG4, in which the amino acid proline is substituted for amino acid residue 228, a glycoprotein with the molecular weight of 149,000 Da composed of four heavy chains (447 amino acid residues each) and two light chains (218 amino acid residues each) [33].

Pembrolizumab targets PD protein 1 and is a novel human mAb. This mAb can target PD-1 receptors with high affinity in both antigen-presenting cells (APCs) and tumors; thus, PD-L1 and PD-L2 are inhibited in the PD-1 pathway. In a tumor microenvironment, pembrolizumab can reactivate antitumor T lymphocytes and stimulate them to become more effective. Pembrolizumab has been approved by the US Food and Drug Administration (FDA) for patients with metastatic ESCC. Despite their infrequency, pembrolizumab can cause some adverse reactions. However, pembrolizumab does not have as many adverse effects as conventional cytotoxic drugs. The first-line use of pembrolizumab in combination with standard CT and the locally advanced use of pembrolizumab combined with definitive chemoradiation are currently being evaluated. An EC trial using pembrolizumab monotherapy showed superior survival to standard CT [34]. There is also a positive overall score of 10 for pembrolizumab monotherapy in patients with advanced ESCC. Treatment of advanced EC patients with

pembrolizumab plus CT has a higher efficacy (45%) as compared to treatment with CT alone (30%) [33, 35] (Fig. 1).

Recent studies have shown that checkpoint inhibitors nivolumab and pembrolizumab are effective in advanced EC patients. There are still some concerns following the current results of large clinical trials. This is even though they have shown high efficacy, tolerable toxicity, and promising survival rates [35]. Despite the obtained results, it is still not clear which combination therapy can have the greatest therapeutic effect for advanced EC patients.

A trial with treated patients with EC found that pembrolizumab monotherapy might prove efficacious. In addition, the present review study revealed that pembrolizumab provides better efficiency in patients with ESCC than in patients with esophageal adenocarcinoma (EAC), suggesting that therapeutic approaches for ESCC and EAC need to be revised. As well as the combined positive score (CPS) (lymphocytes, macrophages, and number of PD-L1-positive cancerous cells divided by the total number of tumor cells) this trial evaluated the expression of PD-L1 and it was found to be indicative of pembrolizumab efficacy [36, 37].

Therapeutic effect of atezolizumab mAb in esophageal cancer

Atezolizumab is a synthetic humanized IgG1 mAb that targets the PDL-1 molecule. This drug became the first FDA-approved mAb to treat urothelial cancer in 2019. The structure of the antibody demonstrates that atezolizumab can bind to PD-L1 with a discrete heavy and light chain orientation and it suppresses the interplay of PD-1 to PDL-1 *via* interfering with PD-1 attachment to PDL-1. Additionally, PD-L1-expressing cancer cells can interact with T cells expressing PD-1 receptors, impairing the immune response against tumors. PD-L1 and PD-1 blockade triggers a T cell immune response in response to cancer. PD-L1 syndrome can be treated with several medicines, including durvalumab and atezolizumab [38]. The presence of PD-L1 expression appears to be associated with the ability to predict the response to treatment, but its ability to predict an anti-tumor response remains to be explored [39].

According to a multicenter phase II proof-of-concept study, atezolizumab (Tecentriq) was demonstrated to be an effective and safe treatment for patients with locally advanced ESCC following chemotherapy. When atezolizumab was combined with CT, the complete response (CR) rate was obtained. Achieving a CR refers to the absence of all detectable cancer after treatment. It is important to note that a complete response does not guarantee a cure, but it represents the best possible outcome.

An increase in expression of PD-L1 and activation of epidermal growth factor receptor (EGFR), extracellular signal-regulated kinases (ERK), and PD-L1 was observed in ESCC cell line cultures treated with CT. Some studies used an EGFR inhibitor (erlotinib) as well as a MAPK/MEK inhibitor (AZD6244) after CT to prevent upregula-

tion of PD-L1 as a result of CT. Consequently, CT combined with anti-PD-L1 immunotherapy is likely to be effective in treating ESCC [40-42]. It was also reported in a phase III study that atezolizumab monotherapy was as effective as regorafenib, a tyrosine kinase receptor blocker, for chemotherapy-refractory metastatic colorectal cancer (mCRC) as compared to atezolizumab and cobimetinib (MEK1/2 inhibitor) [43]. Also, in patients who received atezolizumab, 55.1% were given sorafenib. Atezolizumab has been shown to be a significant improvement over sorafenib; hence it may replace it as a first-line treatment in the near future. There are a number of other clinical trials currently underway involving anti-PD-1/PD-L1 antibodies combined with tyrosine kinase inhibitors (TKIs) or cytotoxic T-lymphocyte-associated protein 4 (CTLA-4) antibodies [44, 45]. In this regard, atezolizumab was well tolerated and had an acceptable safety profile in heavily pretreated patients with advanced EC [46].

Interestingly, CROSS-based neoadjuvant chemoradiotherapy (nCRT) in combination with atezolizumab has never before been used to treat resectable esophageal adenocarcinoma (rEAC). Atezolizumab was found to be feasible for the study population, with 85% of the participants receiving the drug for its entire duration [47]. During the trial, atezolizumab was combined with nab-paclitaxel and carboplatin for neoadjuvant treatment of rEAC cancer. As a result, it is possible that paclitaxel or nab-paclitaxel and atezolizumab caused the dermatologic reactions [48]. Therefore, the addition of atezolizumab to conventional nCRT for rEAC did not adversely affect the surgical outcomes [47].

Therapeutic effect of avelumab in esophageal cancer

Avelumab (Bavencio) is another anti-PD-L1 mAb which is a fully human antibody (IgG1) and it has demonstrated promising results against tumors and potential safety [49].

The FDA has approved three monoclonal antibodies targeting PD-L1: durvalumab, atezolizumab, and avelumab. According to findings presented at the 2019 ASCO Conference, neoadjuvant CT and RT with avelumab are effective and safe treatments for resectable EC and gastroesophageal junction tumors. During the stage I/II randomized trial, there was a relatively small sample size. There is an urgent need to study neoadjuvant CRT combined with avelumab in the treatment of patients with EC and gastroesophageal junction tumors [50]. Avelumab was approved for use in Asia and subsequently it was approved in the United States too, since this trial demonstrated its effectiveness [51, 52].

Treatment of patients with gastric cancer/gastroesophageal junction cancer (GC/GEJC) can be achieved with avelumab. Interestingly, avelumab has approval for metastatic urothelial carcinomas among other solid tumors [49, 53]. In patients with advanced GC/GEJC who

received avelumab as part of the phase I JAVELIN trial it was found that the drug was effective as either a second-line maintenance treatment or first-line maintenance treatment [54]. Actually, it was the primary objective of that study to show that avelumab provides higher overall survival as compared to CT. To indicate the priority of avelumab over CT, the drug was compared with CT. In addition to the primary objective, secondary objectives included the evaluation of progression-free survival (PFS) and objective response rate (ORR) based on assessments by the independent review committee (IRC) [52].

Additionally, when compared with CT, avelumab has a superior safety profile. The study conducted by Bang *et al.* [52] also indicated that avelumab was associated with fewer treatment-related adverse events (TRAEs) than CT. As a result of these findings, avelumab is well tolerated when combined with CT in patients with GC/GEJC, suggesting that it may be used in late stages of the disease for both combination therapy and maintenance treatment. The optimal strategy for incorporating checkpoint inhibitors earlier in the treatment process for patients with advanced GC/GEJC remains unclear; replacement anti-PD-1/PD-L1 therapeutic approaches are required [52]. Eventually, there was a durable response to avelumab treatment in patients who were heavily pretreated with this drug regardless of whether the tumors expressed PD-L1 [55].

Nivolumab antibody: Neoadjuvant for recurrent esophageal cancer

The fully human mAb nivolumab is a drug that inactivates PD-1 and triggers antitumor activities. Researchers found that nivolumab monotherapy significantly improved survival when compared with taxane as a second-line treatment for advanced ESCC patients. Moreover, nivolumab monotherapy after neoadjuvant CT followed by surgery improved disease-free survival significantly compared to placebo in patients with resectable EC and residual pathology.

Nivolumab is the recommended treatment for patients with advanced ESCC following neoadjuvant CT and surgery. First-line treatment options include CT, RT, and neoadjuvant CT containing nivolumab, as well as cytotoxic agents and nivolumab combined with other drugs. There should be improvements in the clinical protocols for EC clinical trials in order to improve the clinical outcomes. In addition to targeting protein 1 of the PD pathway, nivolumab is also an IgG4 mAb to target protein 2 of the PD pathway. Based on the results of the ATTRACTION3 phase III trial, the FDA approved nivolumab monotherapy as a treatment option for patients who have progressed following fluoropyrimidine and platinum-based systemic CT for advanced, recurrent, or metastatic ESCC. The efficacy of adjuvant nivolumab monotherapy in the CheckMate 577 trial was greater than that of placebo in patients who did not achieve a pathologic CR after neoadjuvant CT [56].

The standard course of treatment for ESCC is neoadjuvant CT followed by surgery. Nivolumab was successfully used to treat metastatic ESCC. The effectiveness and safety of nivolumab as a neoadjuvant therapy for ESCC have not yet been evaluated [57].

Despite widespread use of neoadjuvant CT and RT, the recurrence rate is high in both GEJC and EC. In a global, randomized, double-blind phase III trial, nivolumab was used as adjuvant therapy for patients with GEJC and patients at high risk of recurrence following nCRT and gastroesophageal junction resection [58]. Results of this clinical trial study showed that nivolumab adjuvant therapy remarkably prolonged disease-free survival. In an early phase II trial, CheckMate 577, the aim was to determine whether nivolumab adjuvant therapy could be effective in improving disease-free survival among patients with resectable, locally advanced esophageal and GEJC [59].

Despite poor prognoses, nivolumab resulted in an improvement in disease-free survival, reducing recurrence or mortality risk by 31%, and extending median disease-free survival by twice as long as the control group. The hazard ratio for nivolumab over placebo was considerably higher for most prespecified subgroups, including histology (SCC and ACE) and lymphoma status [60]. Notably, in the treatment of patients with advanced gastroesophageal cancer who have previously been treated as well as those who have low levels of PD-L1 expression in tumor cells, nivolumab does not produce any differences in clinical benefit [61, 62]. Combining PD-L1, PD-L2 and PD-L1 expression enhances the effectiveness of checkpoint inhibitors more efficiently than the expression of PD-L1 alone [63].

The CheckMate 577 trial revealed that adjuvant nivolumab was equally effective regardless of the level of PD-L1 expression within tumor cells. The hazard ratio for disease recurrence or death among patients with EC was greater than that for patients with GEJC. After treatment with nivolumab, people with EC and GEJC had similar disease-free survival rates. However, those who received a placebo had a longer median disease-free survival than those with EC, and individuals with GEJC had an even longer median disease-free survival. As a result of nivolumab-adjuvant therapy, recurrences and deaths were 26% lower, as were metastasis-free survival rates, which were 10.7 months longer than those without nivolumab treatment [60]. Moreover, there are positive findings in the CheckMate 577 trial, in which nivolumab has shown promising results in adjuvant treatment of esophageal and GEJCs following melanoma [64].

Nivolumab adjuvant therapy has demonstrated similar safety profiles in other studies in patients with gastroesophageal cancer and other solid tumors [61, 62, 64-66]. The trial regimen was discontinued because of serious adverse events or adverse outcomes associated with nivolumab. Patients with resected EC or GEJC after neoadjuvant CT were significantly more likely to survive disease-free

after nivolumab adjuvant therapy. Nivolumab exhibits a similar safety profile to other types of solid tumors [60]. As matter of fact, although nivolumab is effective in the patients, its serious adverse complications are also reported. Therefore, the use of nivolumab was not continued.

Camrelizumab monoclonal antibody in esophageal cancer

As a selection of mAb against IgG4-kappa PD-1 with humanized chains, camrelizumab (SHR-1210) could be applied to treat PD-1 mutations. The treatment of patients with relapsed or refractory classic Hodgkin lymphoma was conditionally approved through an approved clinical trial conducted by Jiangsu Hengrui Medicine Co., Limited in 2019 [67-69].

Immunotherapy, particularly anti-PD-1 antibodies, has shown improved overall survival in patients with advanced solid tumors after treatment with immune-related adverse events (irAEs). It has been reported that the most common serious adverse event associated with camrelizumab is reactive cutaneous capillary endothelial proliferation (RCCEP). Despite its widespread occurrence in the skin, oral RCCEP has rarely been reported. It will also become common for oral RCCEP to be used in solid tumors in addition to camrelizumab. Surgery and ligation treatment of RCCEP are both associated with a good prognosis [70].

Three additional indications were approved of camrelizumab in China in 2020: (a) patients with malignant hepatocellular carcinoma who had previously received sorafenib and/or oxaliplatin as systemic CT; (b) in combination with pemetrexed and carboplatin to treat locally advanced or metastatic nonsquamous non-small cell lung cancer (NSCLC) without EGFR or ALK mutations; or (c) as a second-line treatment for locally advanced or metastatic ESCC.

As a first-line therapy, definitive RT plus camrelizumab has been evaluated for patients with locally advanced ESCC who were not eligible for or refused concurrent chemotherapy (CCRT). Efficacy of RT as a first-line treatment for metastatic ESCC has been assessed in combination with camrelizumab mAb against PD-1. Locally advanced ESCC was successfully treated with camrelizumab and RT. Further research seems to be necessary in order to identify clinically useful biomarkers. There was some evidence that RT plus camrelizumab was safe and effective as a first-line treatment for patients with locally advanced ESCC. This study demonstrated that a novel first-line treatment combination combining RT and camrelizumab showed promising antitumor activity and manageable toxicity in patients with locally advanced ESCC [67-69]. Patients with advanced or metastatic ESCC face a challenging diagnosis with limited therapeutic options. After undergoing CT, camrelizumab was compared to the CT employed by investigators in patients previously treated with this antibody to determine its efficacy and

safety. The researchers found a remarkable enhancement in survival for patients with ESCC treated with camrelizumab compared with CT. It was also possible to manage the product's safety profile. The treatment may be considered as a standard option for the treatment of patients with esophageal squamous cell carcinoma as a second line of treatment [71].

As a treatment adoption for advanced or metastatic malignant cancers, camrelizumab as a novel inhibitor of PD-L1 is being investigated, including ESCC, GEJC, hepatocellular carcinoma, nasopharyngeal cancer and NSCLC. The results of clinical trials revealed the remarkable increase in overall survival by a spectrum of irAEs due to its hyper-activation of the immune system. It is often associated with digestive disorders, liver disorders, endocrine disorders and skin disorders. Actually, it depends on the etiology of the primary tumor as to what skin lesions occur. On the other hand, pembrolizumab and nivolumab also have irAEs associated with them, but camrelizumab's most common irAE is RCCEP, which usually occurs on skin that is exposed to it. It occurs most commonly on the head, face or trunk of the body and is one of the most common adverse reactions to camrelizumab. The side effects of camrelizumab are likely to include RCCEP in about 80% of patients. RCCEP can be easily confused with other disorders, such as angioma, epulis, or even tumor; however, there are a few cases reported with RCCEP in the eyes, nose, and oral cavity [70, 72].

Tislelizumab antibody

In an effort to develop a new immunotherapy and anti-neoplastic therapy, BeiGene is developing tislelizumab, a monoclonal IgG4 antibody that targets the PD-1 receptor on human cells [73]. There is an approval for the PD-1 mAb tislelizumab that has high affinity and specificity, for the treatment of advanced NSCLC, classical Hodgkin lymphoma, and metastatic PD-L1-high urothelial carcinomas [74, 75].

In patients with advanced unresectable or metastatic ESCC, there is already significant evidence that immune therapy utilizing tislelizumab can improve survival over CT [76]. As well as its preliminary anti-tumor properties, tislelizumab has been demonstrated to be safe among cancer patients. Furthermore, tislelizumab has been applied in ESCC patients and the current evidence indicates that immune checkpoint inhibitors (ICIs) can be used as neoadjuvant therapies. We hypothesized that tislelizumab combined with CT could provide a valuable treatment option for surgically resectable ESCCs [75, 77]. To assess the efficacy and safety of tislelizumab in combination with CT for patients with resectable ESCC, some studies examined tislelizumab plus CT as neoadjuvant therapy. Treatment-naive patients were given carboplatin, nab-paclitaxel, and tislelizumab as neoadjuvant therapies. In the mentioned study, the primary outcome was the major pathological

response (MPR) of the patients undergoing surgery. It has been shown that tislelizumab plus CT is an effective neoadjuvant treatment for resectable ESCC with high rates of resection of MPR, pathological complete response (pCR), and R0 lesions with acceptable tolerability [78].

Another study, the phase III trial RATIONALE-306 (NCT03430843), compared tislelizumab monotherapy with CT (taxane or irinotecan) for the treatment of metastatic or recurrent ESCC. The phase III trial RATIONALE-302 is currently being conducted in patients with metastatic or recurrent ESCC who have not previously received CT (5-FU + platinum or paclitaxel + platinum). It is currently being evaluated whether CT is effective in conjunction with nivolumab and pembrolizumab as a first-line treatment (CheckMate 648, KEYNOTE-590) as well as whether CT combined with tislelizumab is effective as a second-line or first-line treatment (NCT03783442, NCCT03430843) [79]. This phase II study (NCT03469557) evaluated the tolerability, safety and antitumor activity of tislelizumab against PD-1 in combination with CT in patients with locally advanced or metastatic ESCC or GEJC adenocarcinoma. With manageable side effects, tislelizumab plus CT has been reported to be effective in treating metastatic ESCC or gastric/gastroesophageal junction (G/GEJ) adenocarcinomas (ACCs) [80-82].

Durvalumab in esophageal cancer

Another anti-PD-L1 mAb is durvalumab, applied in patients with NSCLC. In the PACIFIC clinical trial, the researchers compared the effects of durvalumab on patients suffering from locally advanced NSCLC. In all patients, the primary endpoints were the probability of survival and overall survival. When compared to placebo, durvalumab significantly improved the life expectancy of patients with locally advanced NSCLC [79, 83].

Additionally, immunotherapy with durvalumab has been shown to be promising in early clinical trials in patients with GEJC [84]. The phase III study will utilize neoadjuvant-adjuvant durvalumab plus FLOT (5-fluorouracil-leucovorin-oxaliplatin-docetaxel) CT followed by adjuvant durvalumab monotherapy for patients with resectable GEJC [84]. Durvalumab proved to be an effective consolidation therapy for patients undergoing platinum-based chemoradiation therapy for stage III NSCLC in the phase III PACIFIC study (NCT02125461) [85]. According to updated results from the phase III CASPIAN study (NCT03043872), durvalumab combined with etoposide and cisplatin/carboplatin demonstrated a sustained overall survival (OS) benefit in patients with extensive-stage small-cell lung cancer (ES-SCLC) [86, 87]. The combination of a single priming dose of tremelimumab, a fully human mAb that targets CTLA-4, plus durvalumab in STRIDE displayed superior efficacy vs. sorafenib, and durvalumab monotherapy was noninferior to sorafenib. Both treatments had a favorable benefit-risk

profile vs. sorafenib in patients with unresectable hepatocellular carcinoma. Based on improved immunotherapeutic responses in the presence of CT, durvalumab combined with FLOT may be considered for patients with resectable GC/GEJC [88-90]. In the randomized, open-label, phase III CheckMate 649 study, nivolumab in combination with CT demonstrated significant improvements in OS and an acceptable safety profile vs. CT alone as first-line treatment for advanced GC/GEJC/EAC [91].

Interestingly, durvalumab not only has the capability of enhancing the function of effector T-cells, but it has also been shown to be effective at eliminating tumor cells by blocking specifically the interaction between PD-L1 and PD-1 [85, 92].

In addition to NSCLC, durvalumab is effective in treating a variety of other tumor types. Moreover, its safety profile is manageable [93].

GC/GEJC that has been resectable and metastatic is being treated with durvalumab, which is being developed based on preliminary data from two early phase clinical trials [94, 95]. Based on these early-phase studies and observations in other tumor types, durvalumab treated patients with GC/GEJC in conjunction with FLOT had better clinical outcomes than patients treated with FLOT alone. Although technological advances have been made in the treatment of GC/GEJC, the 5-year OS rate for patients with resectable tumors remains suboptimal, and it will be necessary to develop new treatments. The use of durvalumab for the treatment of patients with metastatic or recurrent GC/GEJC has shown promising anti-tumor effects. With the combination of FLOT cytotoxic CT and durvalumab, patients with resectable GC/GEJC may experience an improved outcome. A phase III study will assess whether combining perioperative durvalumab with FLOT CT, followed by durvalumab alone, is effective for resectable GC/GEJC patients. The results of this clinical trial study indicate that ICIs can be used as part of a combination CT regimen in neoadjuvant-adjuvant cancer treatment [84].

Ipilimumab antibody; CTLA-4 inhibitor

Immune checkpoint inhibitors are increasingly used to treat cancer due to their ability to reactivate immune cells. Ipilimumab (anti-CTLA-4 antibody), nivolumab (anti-PD-1 antibody), pembrolizumab (anti-PD-1 antibody), atezolizumab (anti-PD-L1 antibody), and durvalumab (anti-PD-L1 antibody) are a number of ICIs that are approved for cancer treatment [96, 97]. Ipilimumab (Yervoy, Bristol-Myers Squibb) binds to the human and canine CTLA-4 and suppresses its interaction with CTLA-4 ligand. For the initial production of the mAb, transgenic mice (HC2/KCo7 strain) expressing the CTLA-4 extracellular domain were used. Research conducted in phase I used antibodies derived from hybridomas 10D1, whereas research conducted in phase II employed Chinese hamster ovary (CHO) cells transfected with vectors containing

heavy and light chains [98]. T cells are capable of upregulating CTLA-4 receptors, which are also targeted by antibodies targeting ICIs. In addition to suppressing T cells, CTLA-4 interacts with APCs in order to accomplish this function. Consequently, CTLA-4 is blocked using, for example, ipilimumab, thus promoting T cell activation [39].

Cancer immunotherapy has been tested with mAbs that target CTLA-4. T-cell-mediated responses are inhibited by CTLA-4. First ipilimumab was found to improve survival in patients with unresectable or metastatic melanoma. Currently, only a combination of nivolumab and ipilimumab has been approved for the treatment of melanoma and other advanced or metastatic solid tumors. The mAb combination may provide better clinical efficacy, but there is an increased risk of irAEs, which can result in patients discontinuing treatment even when they respond to it. Researchers have developed anti-CTLA-4 antibodies that are proteolytically activated in tumor microenvironments, as well as bispecific molecules that target both CTLA-4 and PD-1, which are both expressed by tumor-infiltrating T cells. Additionally, these molecules are less toxic to normal tissues than tumor cells in addition to stimulating immune responses against tumors [99, 100].

Since PD-1 and CTLA-4 are blocked by ipilimumab and nivolumab simultaneously, this combination provides improved clinical efficacy. However, irAEs are more frequent and severe, as the multispecific antibodies (msAbs) inhibit CTLA-4-expressing Treg cells in normal tissues, resulting in a breakdown in immunological tolerance. Generally, severe irAEs may require treatment modifications, such as reducing doses, ceasing treatment, or modifying immunosuppressive therapy [101].

The use of ICIs in cancer treatment has transformed how tumors are treated because they reactivate the immune system in order to eradicate tumor cells. Since anti-CTLA-4 antibodies perform in different directions, when combined with anti-PD-1 (or anti-PD-L1) antibodies, they can have synergistic effects against a wide range of cancer types. It is possible, however, that irAEs may be more frequent in circumstances where there is a strong immune response. In a patient with advanced ESCC receiving nivolumab in combination with ipilimumab, immune-mediated liver damage occurred [102, 103].

Combination therapy or singular immunotherapy?

Several immuno-oncology combination treatments have been tested in first-line trials for treating advanced EC, but the optimal immuno-oncology combination treatment has not been identified [104].

Pembrolizumab

In studies conducted by researchers, it has been determined that pembrolizumab combined with 5-fluorouracil

and cisplatin (PPF) is a superior first-line treatment for EC compared to 5-fluorouracil and cisplatin (PF). In spite of its high cost, however, there is still debate about its value when compared with other forms of competition.

PPF may not be as cost-effective as PF for EC therapy based on the economic perspectives of the USA and China. However, patients with EC and PD-L1 CPS ≥ 10 may gain the most life-years from initial PPF treatment [105].

In Japan, advanced EC treatments are unmet needs. The results of a subgroup analysis in KEYNOTE-181, a randomized, open-label trial involving Japanese patients, were presented. In patients with advanced or metastatic EC who have failed standard first-line therapies, pembrolizumab is used in combination with CT as a second-line treatment. Japanese patients with advanced EC were found to benefit from pembrolizumab as a second-line treatment over CT when it was used as a second-line treatment [106].

KEYNOTE-181 evaluated pembrolizumab as a second-line therapy against CT in patients with advanced squamous cell carcinomas (SCCs) or ACCs. A recent study found that pembrolizumab was associated with a longer overall survival in advanced EC patients with PD-L1 CPS, while exhibiting a better safety profile and comparable quality of life. A second-line treatment option is now considered as the new standard of care for patients with EC and PD-L1 CPS [107].

A phase II study of pembrolizumab demonstrated significant improvements in overall survival over CT when used as the second-line treatment for advanced EC with PD-L1 CPS. In addition to pembrolizumab, pembrolizumab may also benefit PD-L1 CPS patients with EC. This drug is being studied in phase III KEYNOTE-590 (NCT03189719) for use as first-line treatment for advanced EC [107, 108].

Atezolizumab

It has been reported that health care providers have had poor success rates in treating patients with non-resectable locally advanced ESCCs using definitive CRT. It has been shown that the CR rate is strongly correlated with good prognosis, although the factors that determine the likelihood of CR have not been established. In patients with confirmed complete responses (cCR), PFS and OS rates were favorable. An important predictor of cCR was tumor length [109].

Chemoradiotherapy is used to treat ESCC when it is unresectable locally. It contains five fusidic acid metabolites and cisplatin. Only 11 percent to 25 percent of patients achieve a CR, and the median OS is nine to ten months for these patients. Due to their improved therapeutic efficacy, radiation and immunotherapy have received increasing attention.

The PFS and OS of patients with locally advanced NSCLC were significantly improved when platinum-based CRT was followed by anti-PD-L1 antibodies [40].

As part of the management of EC and GEJ adenocarcinoma throughout history, perioperative approaches have been used to improve the pathological CR rate (path CR), minimize or delay metastases, improve resectability, and enhance survival. An inhibitory receptor expressed on T cells, PD-1 and B7-1, performs by inhibiting the actions of PD-L1 on its receptors. As mentioned above, the humanized mAb atezolizumab targets PD-L1 by mimicking immunoglobulin G1. As a result of atezolizumab's therapeutic binding to PD-L1, the T-cell response to tumors can be enhanced. Immunotherapy combined with CT may be of benefit to patients with localized EC or GEJ ACCs. When atezolizumab is administered with oxaliplatin and 5-fluorouracil, there is a high tumor regression rate when the drugs are combined. In order to support further research, atezolizumab should be administered to patients with EC and GEJ undergoing surgery in this trial [110].

Avelumab

There have been some reports of ICI being effective in treating a subset of patients and certain types of tumors. Avelumab mAb has been used in combination with CT to enhance antibody-dependent cytotoxicity. During the course of this study, avelumab was combined with chemotherapeutics, antiangiogenic drugs, and immunomodulators in order to enhance ICI regimens. This report will provide an overview of the current studies investigating the use of avelumab in combination with these agents. As demonstrated in clinical studies, avelumab is effective against Merkel cell carcinomas (MCCs), renal cell carcinomas (RCCs), and urothelial cancers when used alone in patients with cancer. RCC and urothelial cancer can be treated more successfully with avelumab and axitinib combined. In addition to these immunotherapy combination trials, several other immunotherapy trials failed as a result of factors disfavoring their use for ovarian cancer, GC, and NSCLC [111].

Esophageal cancer patients in stages II and III are generally treated with neoadjuvant chemoradiation followed by surgical resection. Approximately 50% of patients who have completed their initial treatment will experience recurrence of the disease. The outcomes are least favorable for resections with residual disease (75%), particularly for cases with ongoing lymph node involvement. Developing new strategies is necessary for improving outcomes. Numerous preclinical and clinical studies have demonstrated the synergy between radiation and immunotherapy. After exposure to CRT in EC, CD8⁺ T lymphocytes are detected infiltrating cancer cells. The microenvironment of the tumor induces an increase in the expression of PD-L1. Metastatic gastroesophageal cancer can be effectively treated with ICIs. The synergistic interaction between radiation and these agents may increase their effectiveness at earlier stages of the disease. Patients with resectable EC will participate in this trial to evaluate avelumab when

combined with CT and radiation. Patients with resectable esophageal carcinoma will be studied in a phase I/II clinical trial using perioperative avelumab plus CRT [112].

Preoperative CT in combination with avelumab did not result in any unexpected side effects. It is likely that neoadjuvant chemoradiation coupled with immunotherapy will prove beneficial to patients with esophageal and GEJ tumors [113].

Nivolumab

Nivolumab inhibits the expression of PD-1 on activated T cells. Although nivolumab has a manageable safety profile, its activity has been encouraging [66].

There is a possibility that this drug could be useful for patients with advanced squamous-cell carcinoma who are unable to respond to existing treatments [79].

PD-1 can be treated with a mAb called nivolumab. It is the third phase of the ATTRACTION-3 project [62, 114].

Nivolumab was demonstrated to be superior to PD-L1-repeated antibodies in the KEYNOTE-181 phase III trial as second-line therapy for all patients with ESCC [107].

Pembrolizumab has been demonstrated to be a superior drug for the treatment of EC compared to other anticancer treatments in phase III trials [79].

Additionally, nivolumab has been developed for the treatment of lymphomas as well as cancers such as EC. ATTRACTION-1, a phase II study, evaluated nivolumab monotherapy for its efficacy. This drug is indicated for the treatment of patients with advanced EC, including EAC and esophageal squamous carcinoma, who have demonstrated a refractory or intolerant response to fluoropyrimidine-based CT, platinum-based CT, or taxane-based CT. This trial included 65 patients with ESCC. An analysis of a central database revealed that 18% of patients responding to nivolumab received the drug. Among other TRAEs, decreased appetite (3%), lung infection (3%), increased levels of creatinine phosphokinase (3%), and dehydration were the most commonly reported. It was demonstrated in the ATTRACTION-1 trial that monotherapy with nivolumab can successfully treat metastatic or recurrent ESCC [114].

When resectable EC is unresponsive to CT and surgery, adjuvant nivolumab monotherapy may be more beneficial. Neoadjuvant chemoradiation is often used in conjunction with neoadjuvant CT. The study of ICIs before and during surgery and CT is necessary to improve the outcomes of these procedures [115].

Camrelizumab

There is a better survival outcome when first-line CT combined with PD-1 inhibitors is used in advanced EC. Additionally, camrelizumab-CT resulted in the longest PFS. CT was the primary factor that improved ORR, in addition to nivolumab [116].

In a study combining PD-1 inhibitors with CT, patients' OS, PFS, and ORR were improved at the expense of greater toxicity, which can be managed. The PFS benefit of sintilimab-chemo and camrelizumab-chemo was greater than that of CT, but there was no difference in OS benefit between checkpoint inhibitor strategies. As a combination of nivolumab and CT, nivolumab was found to improve ORR the most in patients with EC. A significant survival advantage was observed in the group with high PD-L1 expression [116].

Tislelizumab

Efficacy and safety of tislelizumab were evaluated in resectable ESCC patients receiving neoadjuvant treatment. There is evidence that tislelizumab plus CT as neoadjuvant therapy is effective in treating resectable ESCC, and the tolerability of the combination is acceptable. It is well known that tislelizumab in combination with CT results in high rates of MPR, pCR, and R0 resection [78, 117, 118].

A phase II study (NCT03469557) reported an overall response rate of 46.7% and a disease-free survival rate of 80% for GEJ ACCs, respectively [74].

The RATIONALE 302 phase III study produced similar results. Compared to CT, immune therapy with tislelizumab has already shown survival benefits in patients with advanced unresectable/metastatic ESCC [75].

Additionally, preliminary evidence of its antitumor activity has been demonstrated in various types of cancer [117, 119].

In light of strong data showing the safety and efficacy of combined CT and tislelizumab, it has been hypothesized that these treatments could provide an effective therapy for surgically resectable ESCC [78].

Durvalumab

Combining durvalumab monotherapy with durvalumab plus tremelimumab treatment had acceptable results in Asian patients, and the safety profiles were consistent with the published data. According to the preliminary results of the phase I study, durvalumab monotherapy and durvalumab plus tremelimumab had an acceptable safety profile and preliminary clinical activity. There may be potential benefit to further clinical development of durvalumab and tremelimumab in PD-1/PD-L1 and anti-CTLA-4 tumor types when combined with demonstrated safety profiles and preliminary efficacy. Asian patients with ESCC and head and neck squamous cell carcinoma (HNSCC) receiving durvalumab or tremelimumab did not show a significant difference in clinical outcomes between durvalumab monotherapy and durvalumab plus tremelimumab. The previous systemic CT had not been effective for these patients [120].

Ipilimumab

CTLA-4 and PD-1 ICIs are associated with a higher risk of adverse reactions. When patients have multiple adverse reactions to immunotherapy, higher doses of glucocorticoids must be administered and longer courses of therapy must be completed, which greatly increases the risk of complications, such as resurgence of the virus. According to the current guidelines, no information on adverse reactions or complications associated with multiple immune treatments is provided. Early diagnosis and treatment of immune-related adverse reactions are critical for patients with multiple adverse reactions. The future may see more efforts devoted to the study of immune-related complications and adverse reactions. For effective management of multiple immune-associated deleterious reactions, follow-up research is required [102, 121].

In addition to the effect of CTLA4 on interleukin-2 (IL-2) production, CTLA4 expression also plays a role in negatively regulating IL-2 production. In addition, CTLA-4 molecules on the surface of cancer cells prevent the immune system cells from entering the G1 phase, but also reduce the specific immune function and facilitate the escape of tumor cells from the immune system [84]. Several studies have shown that CTLA4 inhibitor can be effective in the treatment of cancer [85].

Currently, there are drugs targeting CTLA-4 in addition to ipilimumab and tremelimumab. The mAb ipilimumab, which blocks CTLA4, is an effective treatment for melanoma [28, 122].

There have been several medical studies conducted with ipilimumab for the treatment of EC, but no trials have taken place in humans. In the phase I/II CheckMate-032 trial (NCT01928394), ipilimumab and nivolumab were combined to treat solid tumors originating from the EC and tested for their efficacy and safety. Among gastroesophageal cancer patients receiving ipilimumab and nivolumab combined, Janjigian *et al.* reported a 6.9 months OS, and no adverse reactions were observed. This finding was consistent with previous reports [28, 123-127].

Cancers that are susceptible to ICIs include a variety of types. This type of therapy is effective only in a small number of patients, such as those who are resistant to PD-1, PD-L2, and programmed cell death-4 (PCD-4). Researchers have conducted preclinical studies showing promise for cancer treatment combinations that include PD-1 or PD-L1 inhibitors, cytotoxic CT, or CTLA-4 antibodies. The use of cytotoxic CT in combination with PD-1/PD-L1 inhibitors has been approved and is now used in clinical trials to treat NSCLC and small cell lung cancer that have shown positive results. Additionally, combination therapies using PD-1 (nivolumab) and CTLA-4 (ipilimumab) have shown survival benefits in patients with melanoma and renal cell carcinoma. There are several ongoing clinical trials evaluating ICI combination thera-

Table 1. Objectives and applications of monoclonal antibodies in esophageal cancer

mAbs	Target	Application	Date of FDA approval	Number of clinical trial
Pembrolizumab	Anti-PD-L1	Salvage-line chemotherapy	On July 30, 2019	KEYNOTE181 (NCT02564263) and KEYNOTE180 (NCT02559687)
Atezolizumab	Anti-PD-L1	Combination with chemotherapy	March 18, 2019	IMpower133
Avelumab	Anti-PD-L1	Combination with neoadjuvant chemoradiotherapy	On March 23, 2017	JAVELIN Merkel 200 trial
Nivolumab	Anti-PD-1	Monotherapy	On June 10, 2020	ATTRACTION-3 (NCT02569242)
Tislelizumab	PD-1	Combination with chemotherapy	July 12, 2022.	RATIONALE 302 trial (NCT03430843)
Durvalumab	Anti-PD-L1	Combination with chemotherapy and radiotherapy	Feb 16, 2018	PACIFIC (NCT02125461)
Ipilimumab	Anti-CTLA-4	Combination with nivolumab and ipilimumab	July 10, 2018	CA209142 (CHECKMATE 142, NCT02060188)

py for the treatment of other types of tumors. Although it is difficult to determine which patients will benefit from PD-1/PD-L1 inhibitor monotherapy, new complementary biomarkers should be developed. ICI combination therapy needs to be studied further to establish appropriate management strategies [128].

There has been speculation about the potential treatment targets CTLA-4 and PD-1 that may be used to combat cytotoxic CTLA-4. Many types of cancer have been treated with pembrolizumab, nivolumab, atezolizumab, and durvalumab, which are approved for PD-1 treatment, as well as PD-L1 inhibitors such as atezolizumab, durvalumab, ipilimumab and tremelimumab that target CTLA-4. In addition, many other clinical trials have reached an advanced stage of development. In addition to inhibiting acquired immune system tolerance, ICIs were observed to enhance antitumor T cell function in response to the tumor microenvironment and cancer cells overexpressing antitumor T cells. ICIs were ineffective as monotherapy for about half of the patients. Combining ipilimumab with nivolumab is commonly used to improve oncological outcomes. Despite promising results, ipilimumab and nivolumab have been hampered by safety concerns [129] (Table 1).

Today, surgery, CT, and RT are the most common treatments for EC. There is currently a wide range of cancers that can be treated with ICIs, including EC. The combination of ipilimumab and nivolumab has been shown to benefit EC models. A combination therapy of nivolumab and ipilimumab showed promising results in patients with EC who did not respond to CT alone, as well as long-lasting antitumor effects [65, 129].

Conclusions

The current development of biomedical materials and therapeutic technologies may soon make it possible to treat

EC more effectively [41]. Although checkpoint inhibitors may be effective in some patients, monotherapy may not be appropriate for all.

Generally, it has been found that combining these agents can improve outcomes in order to overcome this limitation. Whenever immune-associated deleterious effects are not detected and controlled in a timely manner, it is imperative to recognize and control these adverse effects [129]. A major part of immunotherapy is related to ICIs i.e., anti-PD-L1 and anti-CTLA-4, which play a critical role in treatment of patients with metastatic of EC.

It has been concluded that combination therapy could be more effective in patients with ESCC as compared to monotherapy. Actually, combination therapy (CT with immunotherapy) has been successful and reports of recurrence in patients with EC are rare.

Acknowledgments

All authors would like to thank all individuals who assisted in the present review study.

The authors declare no conflict of interest.

References

1. Holmes RS, Vaughan TL (2007): Epidemiology and pathogenesis of esophageal cancer. *Semin Radiat Oncol* 2007; 17: 2-9.
2. Umar SB, Fleischer DE (2008): Esophageal cancer: epidemiology, pathogenesis and prevention. *Nat Clin Pract Gastroenterol Hepatol* 5: 517-526.
3. Kollarova H, Machova L, Horakova D, et al. (2007): Epidemiology of esophageal cancer – an overview article. *Biomed Pap Med Fac Palacky Olomouc Czech Repub* 151: 17-20.
4. Torre L, Bray F, Siegel R, et al. (2015): Global cancer statistics, 2012. *CA Cancer J Clin* 65: 87-108.

5. He H, Chen N, Hou Y, et al. (2020): Trends in the incidence and survival of patients with esophageal cancer: a SEER database analysis. *Thorac Cancer* 11: 1121-1128.
6. Marabotto E, Pellegatta G, Shejjani AD, et al. (2021): Prevention strategies for esophageal cancer – an expert review. *Cancers (Basel)* 13: 2183.
7. Pennathur A, Gibson MK, Jobe BA, Luketich JD (2013): Oesophageal carcinoma. *Lancet* 381: 400-412.
8. Abnet CC, Corley DA, Freedman ND, Kamangar F (2015): Diet and upper gastrointestinal malignancies. *Gastroenterology* 148: 1234-1243.e4.
9. Ohashi S, Miyamoto Si, Kikuchi O, et al. (2015): Recent advances from basic and clinical studies of esophageal squamous cell carcinoma. *Gastroenterology* 149: 1700-1715.
10. Rubenstein JH, Shaheen NJ (2015): Epidemiology, diagnosis, and management of esophageal adenocarcinoma. *Gastroenterology* 149: 302-317.e1.
11. Wang R, Liu S, Chen B, Xi M (2022): Recent advances in combination of immunotherapy and chemoradiotherapy for locally advanced esophageal squamous cell carcinoma. *Cancers* 14: 5168.
12. Zaidi N, Kelly RJ (2017): The management of localized esophageal squamous cell carcinoma: Western approach. *Chin Clin Oncol* 6: 46.
13. Zhang Z, Ye J, Li H, et al. (2022): Neoadjuvant sintilimab and chemotherapy in patients with resectable esophageal squamous cell carcinoma: A prospective, single-arm, phase 2 trial. *Front Immunol* 13: 1031171.
14. Noordzij IC, Curvers WL, Schoon EJ (2019): Endoscopic resection for early esophageal carcinoma. *J Thorac Dis* 11 (Suppl 5): S713.
15. Guerriero JL, Ditsworth D, Fan Y, et al. (2008): Chemotherapy induces tumor clearance independent of apoptosis. *Cancer Res* 68: 9595-9600.
16. Li YJ, Lei YH, Yao N, et al. (2017): Autophagy and multi-drug resistance in cancer. *Chin J Cancer* 36: 52.
17. Shipitsin M, Campbell LL, Argani P, et al. (2007): Molecular definition of breast tumor heterogeneity. *Cancer Cell* 11: 259-273.
18. Kakeji Y, Oshikiri T, Takiguchi G, et al. (2021): Multimodality approaches to control esophageal cancer: development of chemoradiotherapy, chemotherapy, and immunotherapy. *Esophagus* 18: 25-32.
19. Kano K, Aoyama T, Yoshikawa T, et al. (2018): The negative survival impact of infectious complications after surgery is canceled out by the response of neoadjuvant chemotherapy in patients with esophageal cancer. *Ann Surg Oncol* 25: 2034-2043.
20. Kita R, Miyata H, Sugimura K, et al. (2021): Clinical effect of enteral nutrition support during neoadjuvant chemotherapy on the preservation of skeletal muscle mass in patients with esophageal cancer. *Clin Nutr* 40: 4380-4385.
21. Mazaki T, Ebisawa K (2008): Enteral versus parenteral nutrition after gastrointestinal surgery: a systematic review and meta-analysis of randomized controlled trials in the English literature. *J Gastrointest Surg* 12: 739-755.
22. Ryan AM, Reynolds JV, Healy L, et al. (2009): Enteral nutrition enriched with eicosapentaenoic acid (EPA) preserves lean body mass following esophageal cancer surgery: results of a double-blinded randomized controlled trial. *Ann Surg* 249: 355-363.
23. Healy LA, Ryan A, Doyle SL, et al. (2017): Does prolonged enteral feeding with supplemental omega-3 fatty acids impact on recovery post-esophagectomy: results of a randomized double-blind trial. *Ann Surg* 266: 720-728.
24. Murphy RA, Mourtzakis M, Chu QS, et al. (2011): Nutritional intervention with fish oil provides a benefit over standard of care for weight and skeletal muscle mass in patients with nonsmall cell lung cancer receiving chemotherapy. *Cancer* 117: 1775-1782.
25. Silva JdAP, de Souza Fabre ME, Waitzberg DL (2015): Omega-3 supplements for patients in chemotherapy and/or radiotherapy: A systematic review. *Clin Nutr* 34: 359-366.
26. Sultan J, Griffin S, Di Franco F, et al. (2012): Randomized clinical trial of omega-3 fatty acid-supplemented enteral nutrition versus standard enteral nutrition in patients undergoing oesophagogastric cancer surgery. *Br J Surg* 99: 346-355.
27. Bolger JC, Donohoe CL, Lowery M, Reynolds JV (2022): Advances in the curative management of oesophageal cancer. *Br J Cancer* 126: 706-717.
28. Yang YM, Hong P, Xu WW, et al. (2020): Advances in targeted therapy for esophageal cancer. *Signal transduction and targeted therapy. Signal Transduct Target Ther* 5: 229.
29. Barsouk A, Rawla P, Hadjinicolaou AV, et al. (2019): Targeted therapies and immunotherapies in the treatment of esophageal cancers. *Med Sci (Basel)* 7: 100.
30. Noori M, Yousefi A, Zali M, Bashash D. Predictive value of PD-L1 expression in response to immune checkpoint inhibitors for esophageal cancer treatment: A systematic review and meta-analysis. *Front Oncol* 2022; 12: 1021859.
31. Sharpe AH, Pauken KE (2018): The diverse functions of the PD1 inhibitory pathway. *Nat Rev Immunol* 18: 153-167.
32. Salas-Benito D, Pérez-Gracia JL, Ponz-Sarvisé M, et al. (2021): Paradigms on immunotherapy combinations with chemotherapy. *Cancer Discov* 11: 1353-1367.
33. Hato SV, Khong A, de Vries IJM, Lesterhuis WJ (2014): Molecular pathways: the immunogenic effects of platinum-based chemotherapeutics. *Clin Cancer Res* 20: 2831-2837.
34. Yamamoto S, Kato K (2020): Pembrolizumab for the treatment of esophageal cancer. *Expert Opin Biol Ther* 20: 1143-1150.
35. Harada K, Yamamoto S, Kato K (2022): Pembrolizumab for the treatment of advanced esophageal cancer. *Future Oncol* 18: 2311-2319.
36. Hirose T, Yamamoto S, Kato K (2023): Pembrolizumab for first-line treatment of advanced unresectable or metastatic esophageal or gastroesophageal junction cancer. *Therap Adv Gastroenterol* 16: 17562848221148250.
37. Muro K, Hamaguchi T, Ohtsu A, et al. (2004): A phase II study of single-agent docetaxel in patients with metastatic esophageal cancer. *Ann Oncol* 15: 955-959.
38. Abdo J, Agrawal DK, Mittal SK (2017): Basis for molecular diagnostics and immunotherapy for esophageal cancer. *Expert Rev Anticancer Ther* 17: 33-45.
39. Valkema M, Mostert B, Lagarde S, et al. (2023): The effectivity of targeted therapy and immunotherapy in patients with advanced metastatic and non-metastatic cancer of the esophagus and esophago-gastric junction. *Updates Surg* 75: 313-323.
40. Bando H, Kotani D, Tsushima T, et al. (2020): TENERGY: multicenter phase II study of Atezolizumab monotherapy following definitive Chemoradiotherapy with 5-FU plus Cisplatin in patients with unresectable locally advanced esophageal squamous cell carcinoma. *BMC Cancer* 20: 336.

41. He S, Xu J, Liu X, Zhen Y (2021): Advances and challenges in the treatment of esophageal cancer. *Acta Pharm Sin B* 11: 3379-3392.
42. Zhang B, Wang X, Li Q, et al. (2019): Efficacy of irinotecan-based chemotherapy after exposure to an anti-PD-1 antibody in patients with advanced esophageal squamous cell carcinoma. *Chin J Cancer Res* 31: 910-917.
43. Overman MJ, Lonardi S, Wong KYM, et al. (2019): Nivolumab (NIVO)+ low-dose ipilimumab (IPI) in previously treated patients (pts) with microsatellite instability-high/mismatch repair-deficient (MSI-H/dMMR) metastatic colorectal cancer (mCRC): Long-term follow-up. *Am Soc Clin Oncol* 37: 635.
44. Eso Y, Seno H (2020): Current status of treatment with immune checkpoint inhibitors for gastrointestinal, hepatobiliary, and pancreatic cancers. *Therap Adv Gastroenterol* 13: 1756284820948773.
45. Kudo M (2018): Systemic therapy for hepatocellular carcinoma: latest advances. *Cancers (Basel)* 10: 412.
46. Wainberg Z, Matos I, Delord J, et al. (2021): LBA-5 Phase Ib study of the anti-TIGIT antibody tiragolumab in combination with atezolizumab in patients with metastatic esophageal cancer. *Ann Oncol* 32: S227-S228.
47. van den Ende T, de Clercq NC, van Berge Henegouwen MI, et al. (2021): Neoadjuvant chemoradiotherapy combined with atezolizumab for resectable esophageal adenocarcinoma: A single-arm phase II feasibility trial (PERFECT) neoadjuvant PD-L1 inhibition for resectable esophageal adenocarcinoma. *Clin Cancer Res* 27: 3351-3359.
48. van den Ende T, Menting SP, Ambarus CA, et al. (2019): Cutaneous toxicity after chemoradiotherapy and PD-L1 inhibition in two patients with esophageal adenocarcinoma: More than meets the eye. *Oncologist* 24: e149-e153.
49. Patel MR, Ellerton J, Infante JR, et al. (2018): Avelumab in metastatic urothelial carcinoma after platinum failure (JAVELIN Solid Tumor): pooled results from two expansion cohorts of an open-label, phase 1 trial. *Lancet Oncol* 19: 51-64.
50. Li J, Ma S (2021): History and current situation of neoadjuvant treatment for locally advanced esophageal cancer. *Thorac Cancer* 12: 2293-2299.
51. Högnér A, Thuss-Patience P (2021): Immune checkpoint inhibition in oesophago-gastric carcinoma. *Pharmaceuticals (Basel)* 14: 151.
52. Bang YJ, Ruiz EY, Van Cutsem E, et al. (2018): Phase III, randomised trial of avelumab versus physician's choice of chemotherapy as third-line treatment of patients with advanced gastric or gastro-oesophageal junction cancer: primary analysis of JAVELIN Gastric 300. *Ann Oncol* 29: 2052-2060.
53. Apolo AB, Ellerton JA, Infante JR, et al. (2020): Avelumab as second-line therapy for metastatic, platinum-treated urothelial carcinoma in the phase Ib JAVELIN Solid Tumor study: 2-year updated efficacy and safety analysis. *J Immunother Cancer* 8: e001246.
54. Chung HC, Arkenau HT, Lee J, et al. (2019): Avelumab (anti-PD-L1) as first-line switched-maintenance or second-line therapy in patients with advanced gastric or gastroesophageal junction cancer: phase Ib results from the JAVELIN Solid Tumor trial. *J Immunother Cancer* 7: 1-10.
55. Apolo AB, Ellerton JA, Infante JR, et al. (2017): Updated efficacy and safety of avelumab in metastatic urothelial carcinoma (mUC): Pooled analysis from 2 cohorts of the phase Ib Javelin solid tumor study. *Am Soc Clin Oncol* 35, 15_suppl: 4528.
56. Mikuni H, Yamamoto S, Kato K (2021): Nivolumab for the treatment of esophageal cancer. *Expert Opin Biol Ther* 21: 697-703.
57. Yamamoto S, Kato K, Daiko H, et al. (2020): Feasibility study of nivolumab as neoadjuvant chemotherapy for locally esophageal carcinoma: FRONTiER (JCOG1804E). *Future Oncol* 16: 1351-1357.
58. Hindson J (2021): Adjuvant nivolumab for resected gastroesophageal cancer. *Nat Rev Gastroenterol Hepatol* 18: 368.
59. Blum Murphy M, Xiao L, Patel VR, et al. (2017): Pathological complete response in patients with esophageal cancer after the trimodality approach: The association with baseline variables and survival – The University of Texas MD Anderson Cancer Center experience. *Cancer* 123: 4106-4113.
60. Kelly RJ, Ajani JA, Kuzdzal J, et al. (2021): Adjuvant nivolumab in resected esophageal or gastroesophageal junction cancer. *N Engl J Med* 384: 1191-1203.
61. Kang YK, Boku N, Satoh T, et al. (2017): Nivolumab in patients with advanced gastric or gastro-oesophageal junction cancer refractory to, or intolerant of, at least two previous chemotherapy regimens (ONO-4538-12, ATTRACTION-2): a randomised, double-blind, placebo-controlled, phase 3 trial. *Lancet* 390: 2461-2471.
62. Kato K, Cho BC, Takahashi M, et al. (2019): Nivolumab versus chemotherapy in patients with advanced oesophageal squamous cell carcinoma refractory or intolerant to previous chemotherapy (ATTRACTION-3): a multicentre, randomised, open-label, phase 3 trial. *Lancet Oncol* 20: 1506-1517.
63. Lei M, Siemers N, Pandya D, et al. (2019): Association of PD-L1 combined positive score and immune gene signatures with efficacy of nivolumab (NIVO)±ipilimumab (IPI) in patients with metastatic gastroesophageal cancer (mGEC). *Cancer Res* 79 (13_Supplement): 2673.
64. Weber J, Mandala M, Del Vecchio M, et al. (2017): Adjuvant nivolumab versus ipilimumab in resected stage III or IV melanoma. *N Engl J Med* 377: 1824-1835.
65. Janjigian YY, Bendell J, Calvo E, et al. (2018): Check-Mate-032 study: efficacy and safety of nivolumab and nivolumab plus ipilimumab in patients with metastatic esophagogastric cancer. *J Clin Oncol* 36: 2836-2844.
66. Kudo T, Hamamoto Y, Kato K, et al. (2017): Nivolumab treatment for oesophageal squamous-cell carcinoma: an open-label, multicentre, phase 2 trial. *Lancet Oncol* 18: 631-639.
67. Cooper JS, Guo MD, Herskovic A, et al. (1999): Chemoradiotherapy of locally advanced esophageal cancer: long-term follow-up of a prospective randomized trial (RTOG 85-01). *JAMA* 281: 1623-1627.
68. Suntharalingam M, Winter K, Ilson D, et al. (2017): Effect of the addition of cetuximab to paclitaxel, cisplatin, and radiation therapy for patients with esophageal cancer: the NRG oncology RTOG 0436 phase 3 randomized clinical trial. *JAMA Oncol* 3: 1520-1528.
69. Zhang W, Yan C, Gao X, et al. (2021): Safety and feasibility of radiotherapy plus camrelizumab for locally advanced esophageal squamous cell carcinoma. *Oncologist* 26: e1110-e1124.
70. Hua Y, Huang X, Li C, Gao N (2023): An epulis-like camrelizumab related reactive cutaneous capillary endothelial proliferation (RCCEP) in the oral cavity: A case report. *Oral Oncol* 140: 106369.
71. Huang J, Xu J, Chen Y, et al. (2020): Camrelizumab versus investigator's choice of chemotherapy as second-line therapy

- for advanced or metastatic oesophageal squamous cell carcinoma (ESCOR): a multicentre, randomised, open-label, phase 3 study. *Lancet Oncol* 21: 832-842.
72. Luo H, Lu J, Bai Y, et al. (2021): Effect of camrelizumab vs placebo added to chemotherapy on survival and progression-free survival in patients with advanced or metastatic esophageal squamous cell carcinoma: the ESCORT-1st randomized clinical trial. *JAMA* 326: 916-925.
 73. Lee A, Keam SJ (2020): Tislelizumab: first approval. *Drugs* 80: 617-624.
 74. Pinato DJ, Fessas P, Sapisochin G, Marron TU (2021): Perspectives on the neoadjuvant use of immunotherapy in hepatocellular carcinoma. *Hepatology* 74: 483-490.
 75. Wang HY, Yao ZH, Tang H, et al. (2006): Weekly nanoparticle albumin-bound paclitaxel in combination with cisplatin versus weekly solvent-based paclitaxel plus cisplatin as first-line therapy in Chinese patients with advanced esophageal squamous cell carcinoma. *Onco Targets Ther* 9: 5663-5669.
 76. Ychou M, Boige V, Pignon JP, et al. (2011): Perioperative chemotherapy compared with surgery alone for resectable gastroesophageal adenocarcinoma: an FNCLCC and FFCD multicenter phase III trial. *J Clin Oncol* 29: 1715-1721.
 77. Soror T, Kho G, Zhao KL, et al. (2018): Impact of pathological complete response following neoadjuvant chemoradiotherapy in esophageal cancer. *J Thorac Dis* 10: 4069-4076.
 78. Yan X, Duan H, Ni Y, et al. (2022): Tislelizumab combined with chemotherapy as neoadjuvant therapy for surgically resectable esophageal cancer: A prospective, single-arm, phase II study (TD-NICE). *Int J Surg* 103: 106680.
 79. Yamamoto S, Kato K (2020): Immuno-oncology for esophageal cancer. *Future Oncol* 16: 2673-2681.
 80. Feng Y, Hong Y, Sun H, et al. (Eds.) (2019): The molecular binding mechanism of tislelizumab, an investigational anti-PD-1 antibody, is differentiated from pembrolizumab and nivolumab. proceedings of the 110th annual meeting of the American association for cancer research. American Association of Cancer Research, Atlanta, GA.
 81. Xu J, Bai Y, Xu N, et al. (2020): Tislelizumab plus chemotherapy as first-line treatment for advanced esophageal squamous cell carcinoma and gastric/gastroesophageal junction adenocarcinoma. *Clin Cancer Res* 26: 4542-4550.
 82. Xu JM, Kato K, Hubner R, et al. (2019): A randomized, placebo-controlled, phase III trial-in-progress to evaluate the efficacy and safety of tislelizumab plus chemotherapy as first-line treatment for unresectable, locally advanced recurrent/metastatic esophageal squamous cell carcinoma (ESCC). *J Clin Oncol* 37.
 83. Cowzer D, Wu AJC, Sihag S, et al. (2023): Durvalumab and pet-directed chemoradiation in locally advanced esophageal adenocarcinoma – a phase Ib/II study. *Ann Surg* 278: e511-e518.
 84. Janjigian YY, Van Cutsem E, Muro K, et al. (2022): MATTERHORN: phase III study of durvalumab plus FLOT chemotherapy in resectable gastric/gastroesophageal junction cancer. *Future Oncol* 18: 2465-2473.
 85. Antonia SJ, Villegas A, Daniel D, et al. (2017): Durvalumab after chemoradiotherapy in stage III non-small-cell lung cancer. *N Engl J Med* 377: 1919-1929.
 86. Abou-Alfa GK, Chan SL, Kudo M, et al. (2022): Phase 3 randomized, open-label, multicenter study of tremelimumab (T) and durvalumab (D) as first-line therapy in patients (pts) with unresectable hepatocellular carcinoma (uHCC): HIMALAYA. *J Clin Oncol* 40.
 87. Paz-Ares L, Chen Y, Reinmuth N, et al. (2021): LBA61 Durvalumab ± tremelimumab + platinum-etoposide in first-line extensive-stage SCLC (ES-SCLC): 3-year overall survival update from the phase III CASPIAN study. *Ann Oncol* 32: S1338.
 88. Gandhi L, Rodríguez-Abreu D, Gadgeel S, et al. (2018): Pembrolizumab plus chemotherapy in metastatic non-small-cell lung cancer. *N Engl J Med* 378: 2078-2092.
 89. Janjigian YY, Shitara K, Moehler M, et al. (2021): First-line nivolumab plus chemotherapy versus chemotherapy alone for advanced gastric, gastro-oesophageal junction, and oesophageal adenocarcinoma (CheckMate 649): a randomised, open-label, phase 3 trial. *Lancet* 398: 27-40.
 90. Li JY, Chen YP, Li YQ, et al. (2021): Chemotherapeutic and targeted agents can modulate the tumor microenvironment and increase the efficacy of immune checkpoint blockades. *Mol Cancer* 20: 1-21.
 91. Bang YJ, Kang YK, Catenacci DV, et al. (2019): Pembrolizumab alone or in combination with chemotherapy as first-line therapy for patients with advanced gastric or gastroesophageal junction adenocarcinoma: results from the phase II nonrandomized KEYNOTE-059 study. *Gastric Cancer* 22: 828-837.
 92. Stewart R, Morrow M, Hammond SA, et al. (2015): Identification and characterization of MEDI4736, an antagonistic anti-PD-L1 monoclonal antibody identification and characterization of MEDI4736. *Cancer Immunol Res* 3: 1052-1062.
 93. Antonia S, Goldberg SB, Balmanoukian A, et al. (2016): Safety and antitumour activity of durvalumab plus tremelimumab in non-small cell lung cancer: a multicentre, phase 1b study. *Lancet Oncol* 17: 299-308.
 94. Hollebecque A, Wainberg ZA, Ajani JA, et al. (2018): Safety and clinical activity of durvalumab monotherapy in patients with gastroesophageal cancers. *J Clin Oncol* 36.
 95. Kelly RJ, Lee J, Bang YJ, et al. (2020): Safety and efficacy of durvalumab and tremelimumab alone or in combination in patients with advanced gastric and gastroesophageal junction adenocarcinoma. *Clin Cancer Res* 26: 846-854.
 96. Khoja L, Day D, Chen TWW, et al. (2017): Tumour-and class-specific patterns of immune-related adverse events of immune checkpoint inhibitors: a systematic review. *Ann Oncol* 28: 2377-2385.
 97. Thompson JA, Schneider BJ, Brahmer J, et al. (2019): Management of immunotherapy-related toxicities, version 1.2019, NCCN clinical practice guidelines in oncology. *J Natl Compr Canc Netw* 17: 255-289.
 98. Jin G, Guo S, Zhang Y, et al. (2021): Efficacy and safety of KN046 plus nab-paclitaxel/gemcitabine as first-line treatment for unresectable locally advanced or metastatic pancreatic ductal adenocarcinoma (PDAC). *J Clin Oncol* 39 (15 Suppl): 4138.
 99. Lisi L, Lacal PM, Martire M, et al. (2022): Clinical experience with CTLA-4 blockade for cancer immunotherapy: From the monospecific monoclonal antibody ipilimumab to probodies and bispecific molecules targeting the tumor microenvironment. *Pharmacol Res* 175: 105997.
 100. Sugawara K, Iwai M, Ito H, et al. (2021): Oncolytic herpes virus G47Δ works synergistically with CTLA-4 inhibition via dynamic intratumoral immune modulation. *Mol Ther Oncolytics* 22: 129-142.
 101. Price KD, Simutis F, Fletcher A, et al. (Eds.) (2018): Non-clinical safety evaluation of two distinct second generation

- variants of anti-CTLA4 monoclonal antibody, ipilimumab, in monkeys. *Molecular cancer therapeutics*, Philadelphia, PA.
102. Feng Y, Li C, Ji Y, et al. (2022): Nivolumab combined with ipilimumab treatment induced hypophysitis and immune-mediated liver injury in advanced esophageal squamous cell carcinoma: A case report. *Front Oncol* 12: 1309.
 103. Vaddepally RK, Kharel P, Pandey R, et al. (2020): Review of indications of FDA-approved immune checkpoint inhibitors per NCCN guidelines with the level of evidence. *Cancers (Basel)* 12: 738.
 104. Shah MA, Kojima T, Hochhauser D, et al. (2019): Efficacy and safety of pembrolizumab for heavily pretreated patients with advanced, metastatic adenocarcinoma or squamous cell carcinoma of the esophagus: the phase 2 KEYNOTE-180 study. *JAMA Oncol* 5: 546-550.
 105. Zhu Y, Liu K, Ding D, et al. (2022): Pembrolizumab plus chemotherapy as first-line treatment for advanced esophageal cancer: A cost-effectiveness analysis. *Adv Ther* 39: 2614-2629.
 106. Muro K, Kojima T, Moriwaki T, et al. (2022): Second-line pembrolizumab versus chemotherapy in Japanese patients with advanced esophageal cancer: subgroup analysis from KEYNOTE-181. *Esophagus* 19: 137-145.
 107. Kojima T, Muro K, Francois E, et al. (2019): Pembrolizumab versus chemotherapy as second-line therapy for advanced esophageal cancer: phase III KEYNOTE-181 study. *J Clin Oncol* 37.
 108. Kojima T, Shah MA, Muro K, et al. (2020): Randomized phase III KEYNOTE-181 study of pembrolizumab versus chemotherapy in advanced esophageal cancer. *J Clin Oncol* 38: 4138-4148.
 109. Habu T, Kumanishi R, Ogata T, et al. (2023): Complete response to definitive chemoradiotherapy in unresectable locally advanced esophageal squamous cell carcinoma. *Esophagus* 20: 533-540.
 110. Blum Murphy MA, Noguera Gonzalez GM, Sewastjanow-Silva M, et al. (2023): Phase I trial of perioperative chemotherapy plus immunotherapy in localized esophageal and gastroesophageal adenocarcinoma. *J Clin Oncol* 41.
 111. Hamilton G (2021): Avelumab: search for combinations of immune checkpoint inhibition with chemotherapy. *Expert Opin Biol Ther* 21: 311-322.
 112. Uboha NV, Maloney JD, McCarthy D, et al. (2019): Phase I/II trial of perioperative avelumab in combination with chemoradiation in the treatment of stage II/III resectable esophageal cancer. *J Clin Oncol* 37.
 113. Uboha NV, Eickhoff JC, Maloney JD, et al. (2022): Phase I/II trial of perioperative avelumab in combination with chemoradiation (CRT) in the treatment of stage II/III resectable esophageal and gastroesophageal junction (E/GEJ) cancer. *J Clin Oncol* 40.
 114. Leone A, Petrelli F, Ghidini A, et al. (2022): Efficacy and activity of PD-1 blockade in patients with advanced esophageal squamous cell carcinoma: a systematic review and meta-analysis with focus on the value of PD-L1 combined positive score. *ESMO Open* 7: 100380.
 115. Okada M, Yamamoto S, Kato K (2020): Nivolumab for the treatment of esophageal squamous cell carcinoma. *N Engl J Med* 386: 449-462.
 116. Li ZC, Sun YT, Lai MY, et al. (2022): Efficacy and safety of PD-1 inhibitors combined with chemotherapy as first-line therapy for advanced esophageal cancer: A systematic review and network meta-analysis. *Int Immunopharmacol* 109: 108790.
 117. Huang RW, Chao YK, Wen YW, et al. (2014): Predictors of pathological complete response to neoadjuvant chemoradiotherapy for esophageal squamous cell carcinoma. *World J Surg Oncol* 12: 170.
 118. Kulangara K, Guerrero L, Posch A, et al. (2018): Investigation of PD-L1 expression and response to pembrolizumab (pembro) in gastric cancer (GC) and cervical cancer (CC) using combined positive score (CPS) and tumor proportion score (TPS). *J Clin Oncol* 36.
 119. Cunningham D, Allum WH, Stenning SP, et al. (2006): Perioperative chemotherapy versus surgery alone for resectable gastroesophageal cancer. *N Engl J Med* 355: 11-20.
 120. Doki Y, Ueno M, Hsu CH, et al. (2022): Tolerability and efficacy of durvalumab, either as monotherapy or in combination with tremelimumab, in patients from Asia with advanced biliary tract, esophageal, or head-and-neck cancer. *Cancer Med* 11: 2550-2560.
 121. Zhang C, Chen J, Song Q, et al. (2020): Comprehensive analysis of CTLA-4 in the tumor immune microenvironment of 33 cancer types. *Int Immunopharmacol* 85: 106633.
 122. Hodi FS, O'Day SJ, McDermott DF, et al. (2010): Improved survival with ipilimumab in patients with metastatic melanoma. *N Engl J Med* 363: 711-723.
 123. Borghaei H, Paz-Ares L, Horn L, et al. (2015): Nivolumab versus docetaxel in advanced nonsquamous non-small-cell lung cancer. *N Engl J Med* 373: 1627-1639.
 124. Janjigian YY, Bendell JC, Calvo E, et al. (2016): CheckMate-032: Phase I/II, open-label study of safety and activity of nivolumab (nivo) alone or with ipilimumab (ipi) in advanced and metastatic (A/M) gastric cancer (GC). *J Clin Oncol* 34.
 125. Motzer RJ, Escudier B, McDermott DF, et al. (2015): Nivolumab versus everolimus in advanced renal-cell carcinoma. *N Engl J Med* 373: 1803-1813.
 126. Robert C, Long GV, Brady B, et al. (2015): Nivolumab in previously untreated melanoma without BRAF mutation. *N Engl J Med* 372: 320-330.
 127. Weber JS, Gibney G, Sullivan RJ, et al. (2016): Sequential administration of nivolumab and ipilimumab with a planned switch in patients with advanced melanoma (CheckMate 064): an open-label, randomised, phase 2 trial. *Lancet Oncol* 17: 943-955.
 128. Hayashi H, Nakagawa K (2020): Combination therapy with PD-1 or PD-L1 inhibitors for cancer. *Int J Clin Oncol* 25: 818-830.
 129. Kooshkaki O, Derakhshani A, Hosseinkhani N, et al. (2020): Combination of ipilimumab and nivolumab in cancers: from clinical practice to ongoing clinical trials. *Int J Mol Sci* 21: 4427.